**** Suppurative lung diseases :-**

* diseases characterized by → expectoration of large amount of Pus, offensive

① Bronchiectasis


الفروع بتاعة airways لما
divided بتشق
كل ما بتصغر
→ medium sized
organism
microscopic
Cilia
endothelium

* لما الـ organism ينزل ← الـ cilia تطلعه برة.

* Bronchiectasis :- بيحصل على مستوى الـ airways الـ medium ← Chronic Inf, Fibrous walls, Change In composition of mucus → formation of sacs contain large amount of Pus "Polysac" → Colonization of bacteria → Infection, destruction


→ Sacs
→ Pus, Secretions

* Chronic process

الموضوع: ______ التاريخ: / /

→ etiology → ① ~~[illegible]~~ :- ① Congenital

1- ~~bre~~ Primary Ciliary dyskinesia (PCD)

2- Kartagener Syndrome → all ciliated structures all over the body are not functioning - لـ organs مش في مكانها

3- Immunodeficiency In Immunoglobulins as defects In Function of T lymphocytes لـ

② ~~aq~~ acquired :-

1- Virulant Inf as TB, Pertussis, Pseudomon, klebsiella

2- Immunocompromized Pts

3- obstruction "foreign body", "Benign or malignant tumer

Clinical Picture: Couph, wheezing, offensive sput

dyspnea ← lung ← لما أثر على

Chest Pain ← Pleura? ← لو أثر على

Sputum :- ~~virulant~~ Purulent, large amounts, offensive

offensive ?? → Stagnation causes anaerobic Infection

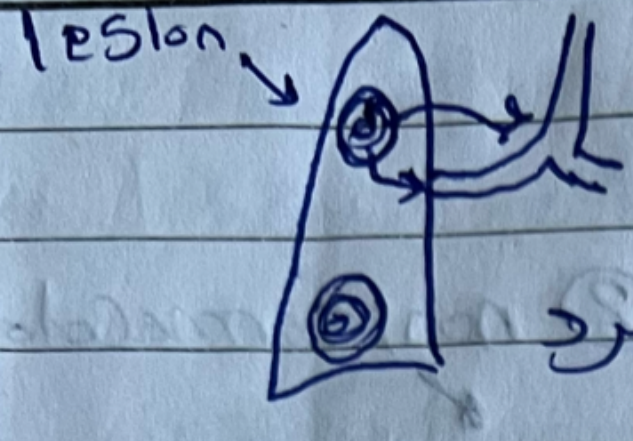

لو عندي lesion في upper side هينزل لوحده
لكن لو تحت (بيتجمع الـ sputum لما ينام (supine
لازم يقعد ويميل عشان يطرد
الـ sputum.

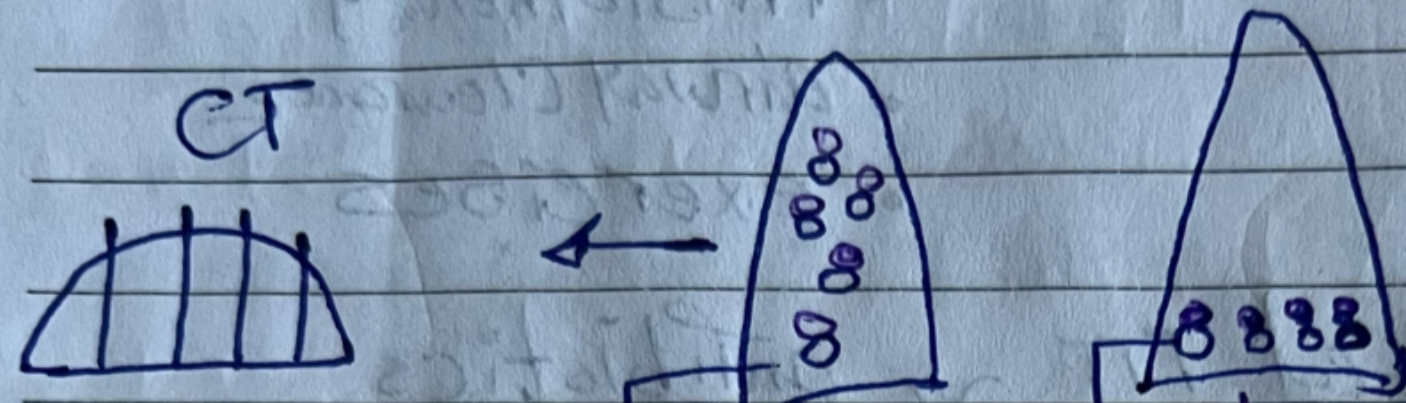

* كل ما بننزل كل ما
بتضيق وكل ~~Bronchi~~
Bronchus معاها artery
normal lung.

هنا الـ Bronchus
وسعت ← الـ artery
صغير أوي.

المفروض
الـ artery
يكون أكبر كل
ما ننزل تحت

* this is called signet ring sign.

* Tram line ← بردو بندور عليها

* loss of tapering → also a sign.

* Fingers in glove opacities = glove stick appearance → mucus filled opaciti. bronchi "filled of pus"

* Complications :- 1- Pneumonia
2- abscess may enter systemic circ
3- organism → may cause brain abscess
4- septicemia 5- Right Ht failure

6- Respiratory failure

TTT :- ① Pharmacological ② nonPharmacological

- Physiotherapy
- airway Clearance
- exercises

* Pharmacological TTT → antibiotics
↲ لان ممكن يحصل Colonization
→ Colonization of G-ve as :-
(i) Pseudomonas → so given
antipseudomonal abx :-
1- Quinolones → ciprofloxacin
↳ levofloxacin
2- Betalactams :-
- 3rd, 4th, 5th gen. Cephalosporins
- Carbapenems
↳ meropenem
↳ Imipenem
- Piperacillin tazobactam
- Aztreonams

Cystic fibrosis
→ Congenital dis
→ Change In Chemical Composition of mucus

moxifloxacin has not antipseudomonal Property

الموضوع: ________ التاريخ: / /

3- Aminoglycoside
4- Polymyxins → Colistin → only Inhalation
* ↓ dose مهم.

- In acute exacerbation $\rightarrow$ TTT For ⑭ days at least
- TTT based on Culture but If we start empirical
→ we cover Pseudomonas

② * Colonization of Staph → Sensitive
→ MRSA

- Sensitive → give macrolides, Tetracyclin, Penicillens, 2nd gen Cephalosporin
- MRSA → Vancomycin, linezolid, teicoplanin

* Does Abx for life?
→ Eradication therapy → Course for 3 months
only for Pts Colonized with Pseudomonas and 1st Isolate "Initial Phase 2 weeks"
⇒ as Pseudomonas is related to mortality and morbidity

→ long term antibiotics → macrolides every other day for 3-6 months then evaluate. → for PTS who have exacerbations more than 2 times / Year
+ Supported medications

ⓒ vaccines

② lung abscess :-

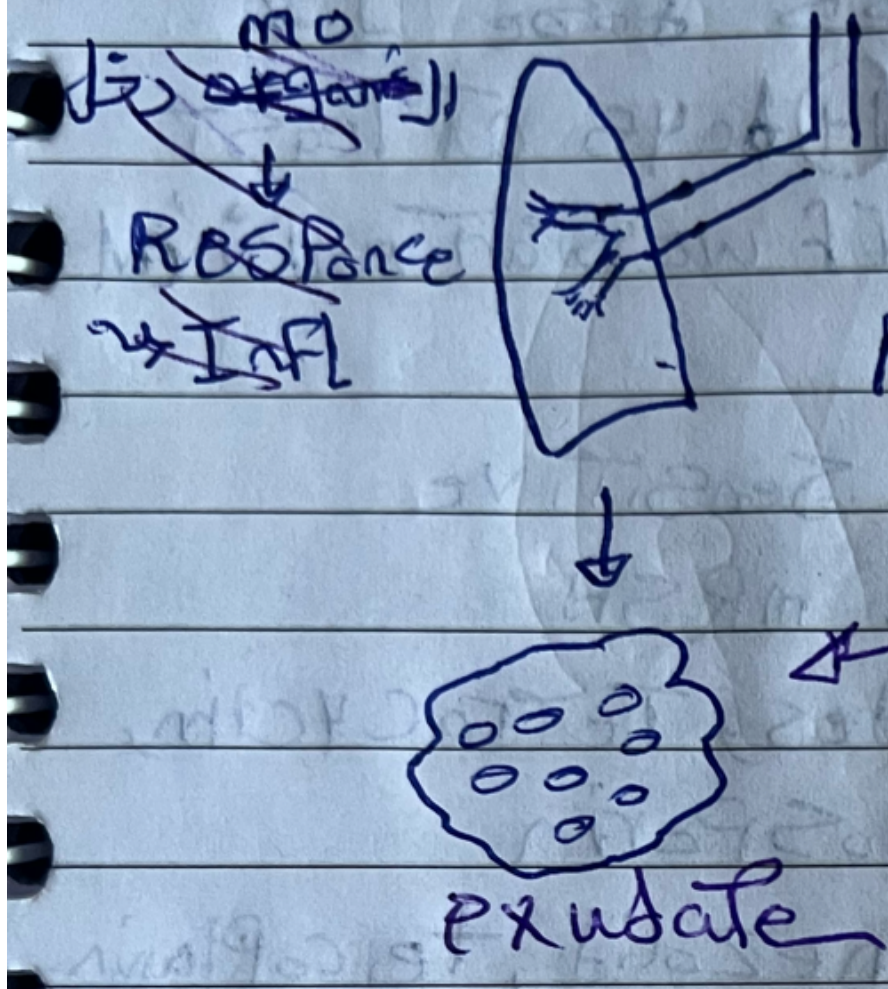

* الـ mo يدخل ف Parenchyma
→ Inflammatory Cell will Respond → alveoli IS filled by exudate

* دا الطبيعي.

* Sometimes this Inflammation IS associated with Necrosis "dead tissue"

→ Same etiology as Bronchiectasis but no Congenital Causes.

Causes :- 1- untreated Pneumonia
2- untreated Bronchiectasis
3- obstruction
4- aspiration
5- Comatosed PTs ← as

* Rhight sided abscesses are most Common.

Cause :- 5- Virulent mo "Staph, klebsiella
⇒ So give anti mRSA and broad spectrum
G-ve

* Clinical Picture :- The same as Bronchectasis
but :- acute and start with crises →
fever, sweating then cough and
large amount, offensive sputum depend on
position of PTs
→ chest pain may occur. (↑ with Inspiration)
→ hemoptysis.

* If abscess Is untreated "chronic" → wall
becomes fibrous material and Inflammation
of artery will occur "end ~~artrites~~ arteritis"
branch of Bronchial artery erosion by fibrous
tissue → ↑ systemic pressure → In
chronic case → bilateral

TTT → antibiotics for 6 weeks →
→ cultured based which cover staph
Gram (-ve), ... ? (In slides)
→ after 6 weeks evaluate :-
→ If There Is > 50% decrease In abscess size
→ good responce to TTT

- If There is < 50% decrease :
  → other organisms as TB, atypical may be present.
- Complications are similar to Bronchiectases

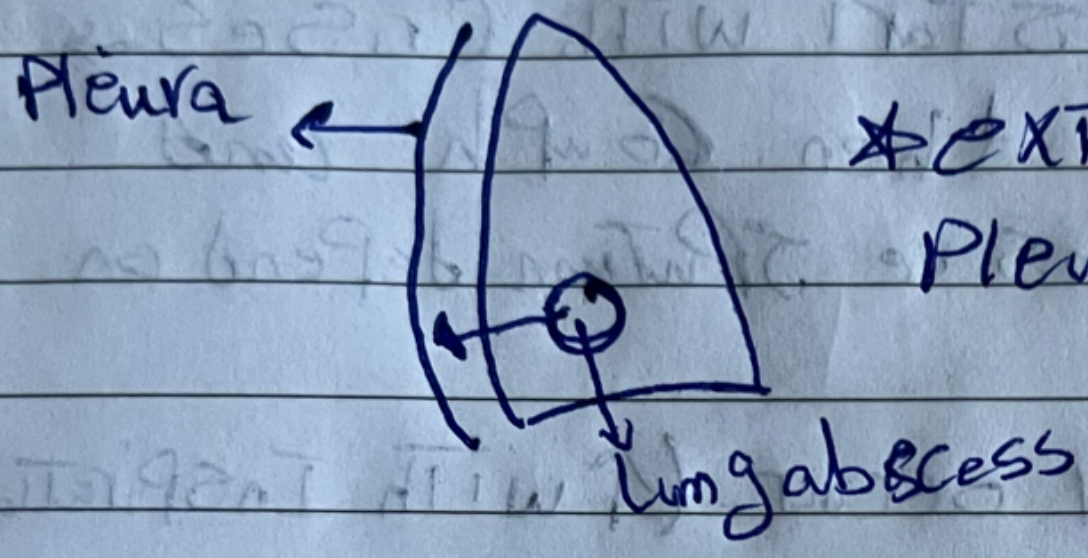

* extension of Pus to The Pleura → empyema
* extension to Bronchus → BPF → Broncho Pleural fistula

→ Diagnosis :- Cavity with air fluid level Inside.

★ Surgical TTT If localized abscess.
→ also In Bronchiectasis "If Intractable and localized"
→ not Common now

③ Empyema with BPF

→ Same antibiotic coverage In empyema

④ Infected cystic lung.

→ Congenital dis

* أجزاء في lung مقفولة

not connected to bronchial tube

الموضوع: مهم: التاريخ: / /

- * antibiotics ✓
- * etiology ✓
- * Complications ✓
- * organism ✓

+ doses + DDIs
+ Durations
+ Interactions

→ Some anti staph Causes Serotonin Syndrome

→ marevan + antibiotics give steroids and anti TB ?

→ Quinolones SE ?